



PATIENT

Bella Doweiko

PRESENTING CLINICAL SIGNS

History: Grade IV/VI left holosystolic murmur. Echocardiogram prior to anesthesia for dental prophy.

SPECIES

Canine

ECHOCARDIOGRAM FINDINGS

2D, m-mode, color flow and Doppler imaging is available.

BREED

Maltese

Left ventricle: The LV diameter is increased with hyperdynamic function. LV wall thicknesses are normal.

Left atrium: The left atrium is severely dilated.

Mitral valve: The mitral valve is diffusely thickened with prolapse into the left atrial lumen. Severe eccentric mitral regurgitation with a normal velocity.

SEX

Female Spayed

Aortic valve/Aorta: The aortic valve appears thickened with borderline increased outflow velocity; laminar flow. No aortic insufficiency.

Right ventricle: Mild RV enlargement.

Right atrium: Mild RA enlargement.

AGE

13 years

Tricuspid valve: The tricuspid valve appears thickened with septal prolapse and severe tricuspid regurgitation. Velocity consistent with moderate pulmonary hypertension.

Pulmonic valve/Pulmonary artery: The pulmonic valve is normal in morphology and mobility. No pulmonic insufficiency. Normal RVOT velocity; laminar flow.

Pericardium/other: No pericardial or pleural effusion noted. No obvious cardiac masses.

WEIGHT

7lbs

Heart rhythm: ECG reveals a sinus rhythm with an average HR of 175bpm.

INTERPRETED BY

Maggie Machen
Lamy, DVM
DACVIM (Cardiology)

2-Dimensional Measurements

Ao diam (cm)	1.0
LA diam (cm)	2.3
LA:Ao (Swe)	2.3
IVS thickness (cm)	0.5
LVID diastole (cm)	2.8
PW thickness (cm)	0.5
LVID systole (cm)	1.3
FS (%)	55

Doppler Measurements

PV Vmax (m/s)	0.7
AoV Vmax (m/s)	1.0
MR Vmax (m/s)	4.9
TR Vmax (m/s)	3.9
TR PG (mmHg)	60

IMAGING PERFORMED BY

Pamela Harrigan,
RDCS

INTERPRETATION OF THE FINDINGS

Chronic degenerative valve disease causing severe mitral and tricuspid regurgitation. The LA is significantly dilated indicating an elevated risk for clinical signs going forward. Significant TR is noted with mild right heart enlargement and elevated pulmonary pressures. No additional concurrent issues are documented.

HOSPITAL NAME

Wood River Animal
Hospital

REFERRING VET

Dr. Schuelke

With this degree of left heart changes, the risk for spontaneous congestive heart failure is elevated and cardiac supportive medications are indicated as below. A weak diuretic (spironolactone) is included given high risk for decompensation in the future even with no reported symptoms. No obvious indication for Sildenafil in the absence of clinical signs; however, monitoring for exertional syncope or dyspnea is recommended. Assessment of progression in the future will help predict long term outcome, however prognosis is guarded at this stage (late B2). Unfortunately, the patient will always be at risk for recurrent CHF, development of arrhythmias/LA tear, syncope and/or sudden death in the future.

INVOICE

22278

DATE

12/5/21



PATIENT

Bella Doweiko

SPECIES

Canine

BREED

Maltese

SEX

Female Spayed

AGE

13 years

WEIGHT

7lbs

RECOMMENDATIONS

- Institute Pimobendan 0.3mg/kg PO q12h.
- Institute ACE-I (benazepril or enalapril) 0.5mg/kg PO q12h.
- Institute spironolactone 1-2mg/kg PO q12h.
- Close monitoring for development of associated clinical signs (development of a cough, labored breathing, exercise intolerance or worsening collapse episodes) is recommended. Monitoring of sleeping breathing rates is recommended as the best way to screen for CHF at home.
- Omega fatty acid supplementation and mild salt restriction may be of some long-term benefit. Mild activity restriction is advised.
- Elective anesthesia is not advised, as there is high risk for complication. If necessary, cardiac protective drug choices (opioid/benzodiazepine premedication, propofol or alfaxalone induction, iso or sevoflurane gas) are recommended. Pre-oxygenate for 5-10 minutes prior to induction and recover in O2 cage. Monitor for arrhythmias, hypotension, and hypoxia both intra and post-operatively and intervene as necessary. Moderate IV fluid restriction is recommended to avoid fluid overload. Avoid heart rate stimulating drugs such as atropine unless clinically indicated.

PLAN

- A renal panel is recommended in 1-2 weeks, then every 3-4 months lifelong.
- Recommend conservative monitoring with a recheck echocardiogram in 6 months, sooner if any development of clinical signs.

INTERPRETED BY

Maggie Machen
 Lamy, DVM
 DACVIM (Cardiology)

IMAGING PERFORMED BY

Pamela Harrigan,
 RDCS

HOSPITAL NAME

Wood River Animal
 Hospital

REFERRING VET

Dr. Schuelke

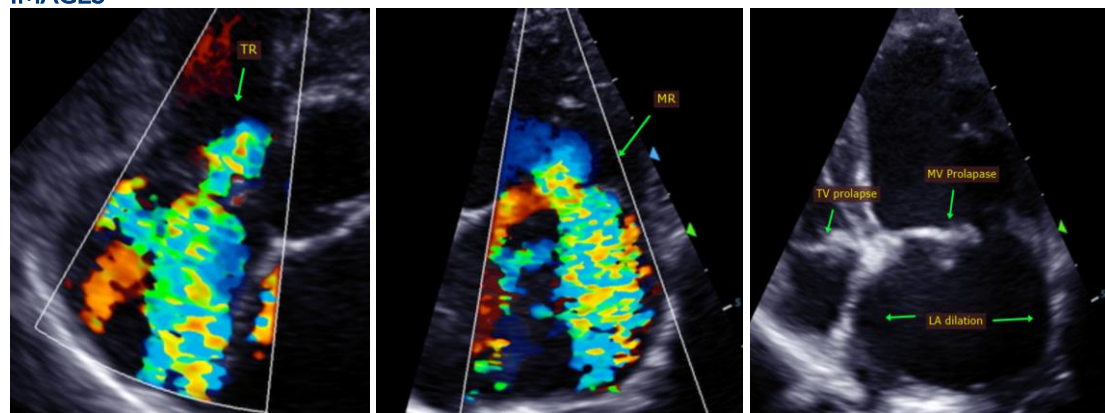
INVOICE

22278

DATE

12/5/21

IMAGES



The information and recommendations provided are based on the images presented by the referring veterinarian. No evaluation can be communicated regarding pathology that was not visible in the image/video clips provided.

Thank you for this referral. This report was generated using transcription software, and minor dictation errors may be present. If the clinical or image interpretation does not parallel your findings or if I can be of any further assistance, please contact me.

Maggie Machen Lamy, DVM
 Diplomate of the American College of Veterinary Internal Medicine (Cardiology)
 info@sonopath.com